

## NEW CONCEPTS IN CAVITY PREPARATION - A REVIEW

**Dr. C. Usha**, Reader

**Dr. Sathyanarayanan. R**, Assistant Professor  
Department of Conservative Dentistry and Endodontics  
Bapuji Dental College & Hospital, Davangeri, Kamataka.

---

### ABSTRACT

Management of carious lesion is assuming a biological approach deviating from the early mechanistic method. Development of adhesive restorative materials and newer generation of silver amalgam has greatly modified Black's principles of cavity preparation. This article reviews the newer concepts in cavity preparation and emphasizes a need for updating to suit the material science advancements.

### INTRODUCTION

In the beginning of the 19th Century G.V. Black advocated a set of basic principles to be followed in a cavity preparation. So exhaustive and thorough were his studies that his principles withstood the test of time till today. However they have been modified extensively in the recent years due to a tremendous development in adhesive restorative dentistry.

Recent modalities of managing carious lesion are more biological than mechanical (1,2,3). Though numerous authors have been advocating such conservative cavity designs since the mid seventies, the conventional cavity preparation is still being taught and practiced in both academic and clinical environs. This may be because of our unchanged examination pattern but nevertheless it is time now to have a fresh outlook and examine whether the

restorative modalities are updated to suit the advantages in material science.

Therefore this article reviews the recent trends in the management of occlusal and proximal lesion with reference mainly to amalgam.

## TREATMENT PLAN

With the introduction of adhesive resins and topical fluoride applications the conventional concept of 'extension for prevention' has been greatly modified to the extent of deletion. It has also been stated that the relatively non self cleansable areas are virtually non existent<sup>4</sup>. Therefore it has become unnecessary to involve healthy tooth structure around a carious lesion other than that which is required to place the cavity margins in accessible areas for finishing and polishing.

If an occlusal lesion is to be restored with amalgam/composite, only the cavitated area needs to be involved in the cavity proper initially. The remaining grooves that are not cavitated should be assessed carefully in terms of cariogenicity and defects like non coalescence to decide upon the following modes of management<sup>5</sup> :

- a. leave them alone! / follow up check up- IF  
low caries index and coalesced.
- b. pit and fissure sealant/ fluoride- IF  
high caries index and non coalesced (FIG 1).

## EXTERNAL OUTLINE FORM

The external outline form assumes a very small size in the new design because of a change in caries pattern in the recent years. The fluoridation process has made the superficial enamel resistant to decay. Nevertheless the caries proceeds through a defective fissure and spreads along the dentino-enamel junction under an apparently intact enamel surface. The ability to remove this identical decay through as limited access as possible will determine the size of the external outline form, not the fissure pattern according to extension for prevention<sup>6</sup>. Of course, the removal of undermined enamel due to lateral decay will also influence the size of external outline form (FIG 2).

The external outline form of a proximal box for an amalgam restoration also follows the same criteria. Extension to the occlusal surface as an occlusal dovetail can be as narrow as one eighth of the intercuspal distance and is necessitated only if

the same is also carious and is continuous with the proximal lesion<sup>3</sup>. If the occlusal and proximal lesions are separated by a safe margin of tooth structure, they have to be treated as two separate cavities (FIG 3). Conservative proximal boxes are made self retentive with proximal retention grooves<sup>7</sup>. The proximal margins of a conservative design are cleared just out of contact to ensure proper finishing and polishing. This should not be confused with extension for prevention.

## INTERNAL OUTLINE FORM

Black's principles recommended a mortise shaped cavity which had its basis on mechanical principles. This required removal of healthy tooth structure in the internal cavity form thus weakening the cuspal elements.

The educators of conservative cavity suggest a more biological rather than mechanistic approach. Since cavity preparation confines only to the carious lesion, removal of all the lesion with a round bur ultimately leaves a conical/pear shaped internal form (FIG 2). The proximal box also acquires the same shape with a gingival seat which is also curved conforming to the contour of the gingival col<sup>8</sup>. Such a shape is claimed to facilitate good adaptation of restorative material especially amalgam (FIG 4).

It has been stated that a flat occlusal or gingival floor either bucco-lingually or mesio distally bears no relation to the shape of the carious lesion and is unnecessary for retention or resistance<sup>9</sup>. Since the laterally spreading lesion at the DEJ is removed through a narrow occlusal opening the cavity automatically assumes an undercut and thus made retentive (FIG 2). In the proximal box, removal of caries from the gingival seat with a round bur results in a pulpally inclined gingival seat which can offer resistance to lateral displacement<sup>8</sup> (FIG 5).

## INSTRUMENTATION

Traditional cavity preparation in Black's era was done with large burs. The large diameter of the bur compensated for slow speed in those times and thus improved cutting efficiency. The result was a wide cavity.

The conservative cavity uses a small pear shaped bur (no. 330) in high speed to gain access to dentinal caries and a round bur to remove the caries<sup>8</sup>. The angulation of a pear shaped bur held parallel to the long axis of a tooth creates a cavo surface angle (CSA) of approximately 105° and an amalgam marginal angle (AMA) of approximately 70° which is very important for the marginal integrity in

an amalgam restorations<sup>6,3</sup>. A parallel sided bur used in conventional cavity created a very high CSA which was not compatible for marginal integrity (FIG 6). As discussed before since a flat floor is not a necessity in recent design, use of inverted cone bur is no longer advised. Gingival marginal trimmer and hatchets are used extensively to remove unsupported enamel and to plane all the walls.

## CONCLUSION

Conservative cavity assumes the size and shape of carious lesion. Extra reduction of tooth structure to satisfy the mechanical principles is deleted. Thus the structural integrity of the tooth is preserved. Moreover in a small cavity preparation the damage to important biological structures like pulp and investing tissues is less. Small sized cavities do not come under direct occlusal load most of the times; thus the longevity of the restoration is guaranteed. Reproduction of the lost occlusal and proximal anatomy in a wide cavity can be difficult and result in alteration of occlusion and inter arch relationship, whereas in a conservative cavity such possibility is less.

Definitely these recent cavity designs have to undergo a strict scientific evaluation in vitro and in vivo so as to provide life long restorations for the patients. A rapid advancement in material science will not be of great significance in improving the quality of services rendered to the patient unless the cavity designs to accomodate them are modified and updated.

## REFERENCES

1. Rodda J.C : Modern class 2 amalgam cavity preparations. *NZ Dent J.*, 68 : 132-138, 1972.
2. Almquist T.C, Cowan R.D, Lambert R.L : Conservative amalgam restoration. *J Prosthet Dent.*, 29 : 524-528, 1973.
3. Elderton R.J : Cavo surface angles, amalgam marginal angles and occlusal cavity preparation. *Br Dent J.*, 156 : 319-324, 1984.
4. Alexander A.G, Morganstein S.L and Bibbons J.W : A study of the growth of plaque and the efficiency of self cleansing mechanisms. *Dent Pract Dent Rec.*, 19 : 293-297, 1969.
5. Pickard H.M : A manual of operative dentistry, 7th Edition; Oxford university press.
6. P.B. Robinson : The evolution of cavity shape for minimal amalgam restoration. *Dent Update.*, 12 : 357-380, 1985.

7. Sturdevant J.R et al : Conservative preparation for minimal designs for class II amalgam restoration. *Dent Matter.*, 3 : 144-148, 1987.
8. Elderton R.J. : New approaches to cavity design. *Br Dent J.*, 157 : 421-427, 1984.

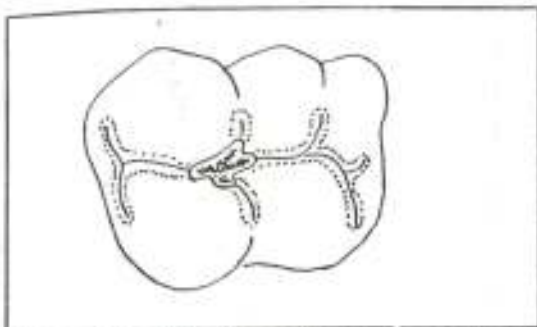


FIG. 1 : Pit and fissure sealant on non cavitated fissure and restoration in cavitated area.

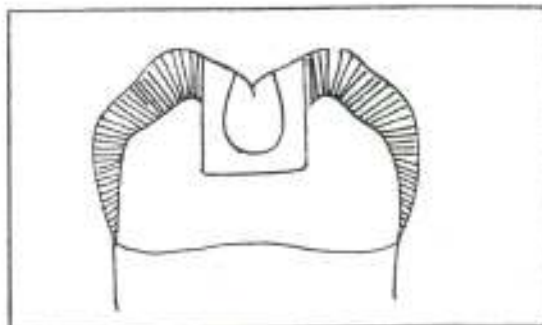


FIG. 2 : Mortise shape of conventional Vs pear shape of conservative cavity.

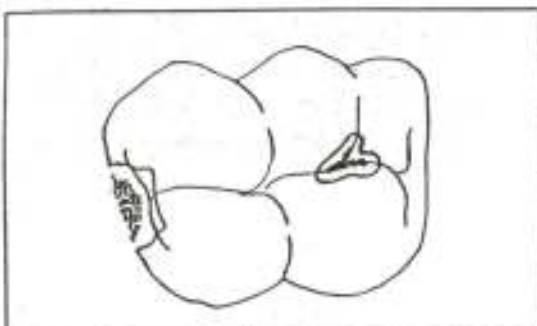


FIG. 3 : Safe margin of tooth structure separating the occlusal and proximal lesion - treated as two separate cavities.

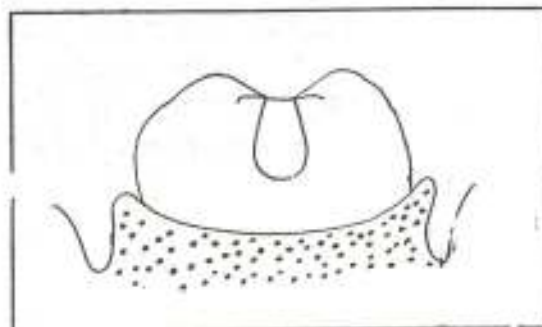


FIG. 4 : The pear shaped proximal box - curved gingival seat conforming to the shape of gingival col.

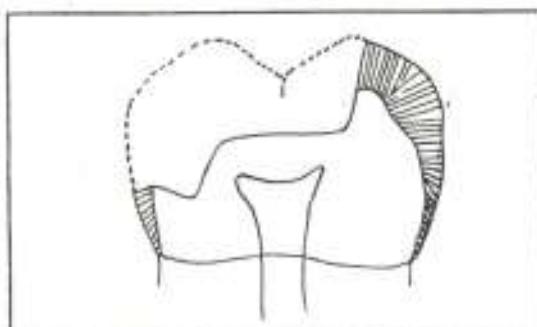


FIG. 5 : Pulpally inclined gingival seat provide resistance and retention form.

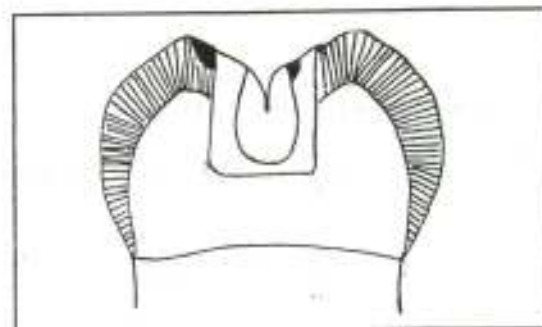


FIG. 6 : Very high cavo surface angle of conventional cavity Vs optimal cavo surface angle of conservative cavity.